

CASE RECORDS of the MASSACHUSETTS GENERAL HOSPITAL

Founded by Richard C. Cabot
Eric S. Rosenberg, M.D., *Editor*
Virginia M. Pierce, M.D., David M. Dudzinski, M.D., Meridale V. Baggett, M.D.,
Dennis C. Sgroi, M.D., Jo-Anne O. Shepard, M.D., *Associate Editors*
Alyssa Y. Castillo, M.D., *Case Records Editorial Fellow*
Emily K. McDonald, Sally H. Ebeling, *Production Editors*



Case 27-2018: A 3-Year-Old Boy with Seizures

Mark P. Gorman, M.D., Grace Y. Gombolay, M.D., William A. Mehan, Jr., M.D.,
and Ronald L. Thibert, D.O., M.S.P.H.

PRESENTATION OF CASE

From the Department of Neurology, Boston Children's Hospital (M.P.G.), the Departments of Neurology (G.Y.G., R.L.T.), Radiology (W.A.M.), and Pediatrics (R.L.T.), Massachusetts General Hospital, and the Departments of Neurology (M.P.G., G.Y.G., R.L.T.) and Radiology (W.A.M.), Harvard Medical School — all in Boston.

N Engl J Med 2018;379:870-8.
DOI: 10.1056/NEJMcpc1802824
Copyright © 2018 Massachusetts Medical Society.

Dr. Caitlin E. Naureckas Li (Pediatrics): A 3-year-old boy was admitted to this hospital during the summer because of a seizure.

The patient had been well until 3 days before admission, when one episode of emesis occurred. The following evening, he was fussy, and on the third day of illness, he had decreased language output and one loose bowel movement. That evening, he told his mother that he wanted to sleep, which was atypical behavior. One minute after the patient lay down, he suddenly sat up; his whole body stiffened, and he did not respond to his name being called. His mother noted that he felt warm to the touch, that his head was turned to the left, and that he appeared to be “staring off into space.” Both arms were flexed, and there were shaking movements of the arms and legs that were greater on the left side than on the right side. After 1 minute, the movements stopped and the patient vomited; he seemed to be confused and then fell asleep. Emergency medical services were called. On examination 10 minutes later, he was somnolent but arousable and had spontaneous movements of the arms and legs. He vomited again and was transported to the emergency department of another hospital, arriving 25 minutes after the episode.

On examination, the patient was alert, active, and in no apparent distress. The temperature was 36.9°C; other vital signs were normal. The weight was 15.8 kg (71st percentile). Strength, sensation, coordination, and cranial-nerve function were normal, as was the remainder of the physical examination. The blood glucose level, obtained by fingerstick testing, was 105 mg per deciliter (5.8 mmol per liter; reference range, 70 to 110 mg per deciliter [3.9 to 6.1 mmol per liter]). The patient vomited, and ondansetron was administered orally. Early the following morning, after a pediatric neurologist was consulted, the patient was transferred to the emergency department of this hospital.

The history was obtained from the patient's mother. There had been no known head trauma or toxic ingestion. The patient had been born after a full-term gestation and had had normal growth and development, except for a previous mild speech delay;

Table 1. Laboratory Data.

Variable	Reference Range, Age-Adjusted, This Hospital*	First Presentation, Emergency Department, This Hospital	Reference Range, Other Hospital	8 Days Later, Emergency Department, Other Hospital
Hemoglobin (g/dl)	11.5–13.5	11.9	10.5–13.5	10.8
Hematocrit (%)	34–40	33.5	33.0–40.0	31.2
White-cell count (per mm ³)	6000–17,000	15,030	4500–11,000	7460
Differential count (%)				
Neutrophils	25–50	59.1	54.0–62.0	66.7
Immature granulocytes	0.0–0.8	0.3	0.0–1.0	0.4
Lymphocytes	50–56	34.4	27.0–60.0	26.9
Monocytes	4–11	5.3	4.7–12.0	5.4
Eosinophils	0–8	0.4	0.0–3.0	0.1
Basophils	0–3	0.5	0.0–1.0	0.5
Sodium (mmol/liter)	135–145	137	133–145	142
Potassium (mmol/liter)	3.4–5.0	4.8	3.4–4.7	3.8
Chloride (mmol/liter)	98–108	96	98–115	101
Carbon dioxide (mmol/liter)	23–32	24	20–28	20
Anion gap (mmol/liter)	3–17	17	3–17	21
Phosphorus (mg/dl)†	4.5–5.5	5.6	4.5–5.5	3.7
<i>Borrelia burgdorferi</i> IgG and IgM antibody screen			Negative	Negative

* Reference values are affected by many variables, including the patient population and the laboratory methods used. The ranges used at Massachusetts General Hospital are age-adjusted and are for patients who do not have medical conditions that could affect the results. They may therefore not be appropriate for all patients.

† To convert the values for phosphorus to millimoles per liter, multiply by 0.3229.

he currently knew at least 200 words and spoke in full sentences. He had not received vaccines for *Streptococcus pneumoniae*, *Haemophilus influenzae* type b, hepatitis B virus, or rotavirus because of parental refusal; he had received other routine childhood vaccines. He did not take any medications or have any known allergies. He lived with his parents and siblings in an urban area of New England. There were no pets at home. There was no family history of seizures.

On examination, the patient was sleeping; he awoke when touched and pushed the examiner away. The temperature was 37.4°C, the pulse 86 beats per minute, the blood pressure 100/59 mm Hg, the respiratory rate 30 breaths per minute, and the oxygen saturation 98% while he was breathing ambient air. The pupils were round, equal, and reactive to light, decreasing from 3 mm to 2 mm in diameter; there was no ptosis. The face was symmetric, with normal forehead wrinkling,

blinking, smiling, and cheek puffing. Muscle bulk and tone were normal, as was strength. The patient withdrew from tickling. Deep-tendon reflexes were 1+ throughout, and plantar reflexes were flexor. The remainder of the examination was normal. The red-cell count, red-cell indexes, platelet count, and results of renal- and liver-function tests were normal, as were blood levels of glucose, calcium, and magnesium; other laboratory test results are shown in Table 1.

Magnetic resonance imaging (MRI) of the head was performed, and a T₂-weighted single-shot turbo spin-echo image showed normal ventricles and no extraaxial fluid collection, mass lesion, or midline shift. Electroencephalography (EEG), performed 12 hours after the seizure, revealed continuous focal polymorphic delta slowing and occasional broad sharp wave discharges over the right frontal region. That afternoon, the patient's temperature was 38.2°C; acetaminophen was adminis-

tered. He was observed overnight and had no seizure activity, and the following morning, he was discharged home.

One week after discharge, the patient was taken back to the emergency department of the other hospital. His mother reported that he had been well for the 2 days after discharge, but for the past 5 days, he had had progressively decreased language output, increased sleep (such that he was now sleeping for most of the day, awakening for only 10 minutes at a time), decreased oral intake, and constipation that could not be relieved by orally administered polyethylene glycol. During the past 2 days, mood lability had developed; there had been periods when he seemed enraged and was physically and verbally aggressive toward family members, as well as periods when he laughed hysterically, and these moods had not been provoked. He had babbled, repeated unusual phrases, and lost interest in games, toys, and videos; his gait had become increasingly unsteady, with frequent tripping. On the day of this presentation, writhing movements had occurred after he ate and drank; his mother thought these movements might have been caused by abdominal pain. In addition, his urine output had decreased.

On examination, the patient was quiet, with a flat affect and subdued behavior. Vital signs were normal; the weight was 14.7 kg (48th percentile). The oral mucous membranes were dry. The abdomen was soft and flat, without tenderness; bowel sounds were normal. The patient followed some commands and then fell asleep during the examination. The remainder of the examination was normal. The blood glucose level, obtained by fingerstick testing, was 76 mg per deciliter (4.2 mmol per liter), and abdominal radiography revealed feces in the colon, without evidence of obstruction. Normal saline was administered intravenously; 1 hour later, the red-cell count, red-cell indexes, platelet count, results of renal- and liver-function tests, and venous blood gas measurements were normal, as were blood levels of glucose, calcium, magnesium, thyrotropin, and free thyroxine. A serum toxicology screen was negative; other laboratory test results are shown in Table 1. Abdominal ultrasonography revealed increased bowel gas, without evidence of intussusception. The patient was transferred to the emergency department of this hospital for further evaluation and treatment.

In the emergency department, the patient was

somnolent but aroused in response to voice; he made only limited eye contact with his parents and the examiner and had unintelligible speech. There was one unprovoked episode of agitation and screaming. Vital signs were normal. The pupils were round, equal, and reactive to light, decreasing from 5 mm to 2 mm in diameter. He blinked in response to threat bilaterally. Extraocular movements were intact, without nystagmus. The face was symmetric, and the tongue was midline. The neck was supple. The patient moved the arms and legs equally and had normal strength and normal sensation to light touch. Deep-tendon reflexes were 2+ throughout. Plantar reflexes were flexor. The gait was unsteady and ataxic. The remainder of the examination was normal. A sodium phosphate-based enema was administered, and the patient had a large bowel movement. He was admitted to the hospital for further evaluation and treatment.

The following day, magnetic resonance angiography of the head was normal. MRI of the head and spine was performed before and after the intravenous administration of contrast material, and fluid-attenuated inversion recovery (FLAIR) images revealed a small number of scattered, punctate, nonspecific hyperintense foci in the white matter of the brain and mild, scattered mucosal thickening in the paranasal sinus, without other abnormalities. A lumbar puncture was performed; the results of cerebrospinal fluid (CSF) analysis are shown in Table 2. A plasma sample was sent for acylcarnitine profile analysis, and tests of a nasopharyngeal swab for adenovirus, parainfluenza virus, and metapneumovirus antigens were negative. Urinalysis revealed a specific gravity of 1.017, a pH of 6.0, and 1+ ketones. Intravenous fluids, acyclovir, and oral acetaminophen and ibuprofen were administered.

During the third and fourth hospital days, the patient had episodes of irritability, thrashing, and screaming, as well as intermittent stereotyped arm movements, athetoid hand movements, and orofacial dyskinesias. Video EEG revealed generalized polymorphic slowing of the resting background (at a rate of 2 to 5 Hz), even while the patient was in a maximally awake state; the abnormal movements had no correlate on EEG. On the morning of the fifth hospital day, apnea occurred, with associated tachycardia, hypertension, opisthotonic posturing, and jaw clenching. Ventilation with a bag-valve-mask device was difficult

Table 2. Cerebrospinal Fluid Analysis.

Variable	Reference Range, Age-Adjusted, This Hospital*	Second Hospital Day, Second Admission, This Hospital
Color		Colorless
Turbidity		Clear
Xanthochromia		None
Red-cell count (per mm ³)		
Tube 1	0–5	46
Tube 4	0–5	9
White-cell count (per mm ³)		
Tube 1	0–5	38
Tube 4	0–5	33
Differential count (%)		
Tube 1		72% lymphocytes, 4% reactive lymphocytes, 24% monocytes
Tube 4		67% lymphocytes, 5% reactive lymphocytes, 23% monocytes, 5% macrophages
Protein (mg/dl)	5–55	29
Glucose (mg/dl) †	50–75	68
Gram's stain		Abundant mononuclear cells, no polymor- phonuclear cells, no organisms seen

* Reference values are affected by many variables, including the patient population and the laboratory methods used. The ranges used at Massachusetts General Hospital are age-adjusted and are for patients who do not have medical conditions that could affect the results. They may therefore not be appropriate for all patients.

† To convert the values for glucose to millimoles per liter, multiply by 0.05551.

to administer. Midazolam, fentanyl, and rocuronium were administered intravenously, the trachea was intubated, and mechanical ventilation was begun; thereafter, the posturing resolved and vital signs normalized. The patient was transferred to the pediatric intensive care unit (ICU).

A diagnosis and management decisions were made.

DIFFERENTIAL DIAGNOSIS

Dr. Mark P. Gorman: This 3-year-old boy had two admissions to this hospital: an initial admission because of a first-time seizure, and a second admission because of symptoms that had developed during the week after discharge, including decreased language output, lethargy, labile mood, aggressive behavior, and unsteady gait. During the second admission, a movement disorder (including orofacial dyskinesias) became apparent, and CSF analysis revealed lymphocytic pleocytosis. Through synthesis of all this information, we can construct a differential diagnosis.

FIRST ADMISSION: FIRST-TIME SEIZURE

Although there are many causes of seizure,¹ several features of this patient's initial presentation may offer helpful clues in this case. First, the vomiting and diarrhea that preceded the initial seizure raise several diagnostic possibilities, including viral gastroenteritis, with or without dehydration or electrolyte abnormalities that lower the threshold for seizure in a susceptible host; benign convulsions with gastroenteritis; a postinfectious inflammatory or autoimmune disorder of the central nervous system (CNS); or a concurrent gastrointestinal and CNS infection. Second, the decreased language output that occurred on the day before the seizure, which was probably localized to the frontal lobe of the dominant (usually left) hemisphere, broadens the differential diagnosis to include stroke, encephalitis (particularly encephalitis associated with herpes simplex virus or anti-N-methyl-D-aspartate [NMDA] receptor antibodies), unrecognized seizures, and the Landau-Kleffner syndrome (a rare form of epilepsy that is characterized by progressive lan-

guage dysfunction in young children with previous age-appropriate development). Third, the low-grade fever that occurred approximately 18 hours after the seizure is of a lower magnitude and later onset than would be expected in a patient with a febrile seizure, and it prompts consideration of a CNS infection or inflammatory disorder, especially in the absence of a clear systemic source of fever. Finally, although the limited results of MRI of the head were normal, EEG showed continuous focal delta slowing and sharp wave discharges over the right frontal region, findings that correlate with the leftward deviation of the head and left side–predominant clonic movements that were observed with the seizure. Thus, although the normal physical examination is reassuring, the vomiting and diarrhea, decreased language output, fever, and focal abnormalities on EEG all raise concerns about encephalitis as the cause of seizure in this patient and suggest that an autoimmune or infectious cause is most likely.

SECOND ADMISSION: ENCEPHALITIS

After a brief hospital stay that followed the seizure, the patient was discharged home, where his clinical status deteriorated. The course was characterized by progressively abnormal language function, lethargy, aggressiveness, and spells of unprovoked laughter (which could have been seizures or hallucinations). On readmission to the hospital, CSF analysis revealed lymphocytic pleocytosis. How does this new information help us to focus the differential diagnosis? At this stage, it is clear that the patient meets the criteria for a diagnosis of encephalitis, which can be defined as the presence of encephalopathy (a depressed or altered level of consciousness that lasts for 24 hours, lethargy, or personality change) in addition to at least one of the following features: fever, seizure, focal neurologic findings, pleocytosis on CSF analysis, or findings consistent with encephalitis on EEG or neuroimaging studies.²

ENCEPHALITIS WITH MOVEMENT DISORDER

Intermittent stereotyped arm movements, athetoid hand movements, and orofacial dyskinesias subsequently developed in the patient. On the basis of the EEG results, these abnormal movements were not due to seizure activity. The presence of this mixed movement disorder allows us to further focus the differential diagnosis. Data from the California Encephalitis Project suggest

that persons with encephalitis and movement or extrapyramidal disorders are most likely to have one of several infectious or postinfectious causes (e.g., measles, subacute sclerosing panencephalitis, enterovirus, varicella–zoster virus, human herpesvirus 6, *Mycoplasma pneumoniae*, or Sydenham's chorea) or noninfectious causes (e.g., lymphoma, small-cell lung cancer, or ovarian teratoma).² Of note, in a retrospective analysis involving patients with encephalitis and dyskinesias or movement disorders without a previously identified cause, anti–NMDA receptor antibodies were present in half the patients.³ It is now understood that anti–NMDA receptor antibodies are a common cause of encephalitis with movement disorder and, more broadly, were the most commonly identified cause of encephalitis among patients 30 years of age or younger in the California Encephalitis Project.⁴ Therefore, testing for anti–NMDA receptor antibodies should be considered early during the evaluation of young patients with encephalitis, particularly those with a presentation similar to that seen in this case.

ANTI–NMDA RECEPTOR ENCEPHALITIS

Clinical criteria provide a means to diagnose probable anti–NMDA receptor encephalitis before the results of confirmatory testing are available (Table 3).⁵ This patient meets all the criteria; however, alternative disorders need to be ruled out. The most relevant alternative disorder to consider in this patient is CNS infection caused by enterovirus or herpes simplex virus, which should be ruled out by means of polymerase-chain-reaction (PCR) assays of the CSF.

To confirm the diagnosis of anti–NMDA receptor encephalitis, I would send serum and CSF specimens to a laboratory that is capable of performing both immunohistochemical and cell-based assays for autoantibodies. Serum testing for anti–NMDA receptor antibodies is 85% sensitive, whereas CSF testing is 100% sensitive. However, serum testing is clinically useful (since serum specimens can be obtained for monitoring more easily than CSF specimens) and can also be helpful in detecting antineuronal antibodies other than anti–NMDA receptor antibodies.⁶

Dr. Virginia M. Pierce (Pathology): Dr. Gombolay, what was your clinical impression when you evaluated this patient?

Dr. Grace Y. Gombolay: We initially thought that infectious meningoencephalitis was the most like-

Table 3. Diagnostic Criteria for Probable Anti-NMDA Receptor Encephalitis.*

Criterion	Findings in This Patient
Rapid onset (<3 mo) of ≥4 of the following symptoms:	
Abnormal (psychiatric) behavior or cognitive dysfunction	Aggressive behavior and unprovoked laughter
Speech dysfunction	Decreased language output and abnormal speech
Seizures	Seizures
Movement disorder, dyskinesias, rigidity, or abnormal postures	Athetosis and orofacial dyskinesias
Decreased level of consciousness	Lethargy
Autonomic dysfunction or central hypoventilation	Episode of apnea, tachycardia, and hypertension
Presence of ≥1 of the following findings:	
Abnormal results on electroencephalography	Focal slowing and sharp wave discharges
Pleocytosis or oligoclonal bands on CSF analysis	CSF white-cell count of 43 per mm ³
Absence of other disorders (e.g., CNS infections and neoplasms, metabolic disorders, and cerebrovascular disease)	
Absence of other disorders	

* Data are from Graus et al.³ CNS denotes central nervous system, CSF cerebrospinal fluid, and NMDA *N*-methyl-D-aspartate.

ly diagnosis. However, our laboratory evaluation for infectious causes of encephalitis was unrevealing; CSF PCR assays for herpes simplex virus, varicella-zoster virus, Epstein-Barr virus, West Nile virus, and *M. pneumoniae* were negative, as were CSF tests for antibodies to *M. pneumoniae* and Powassan virus and serum tests for antibodies to *M. pneumoniae* and Epstein-Barr virus. With the development of choreiform movements, an autoimmune cause such as anti-NMDA receptor encephalitis was thought to be most likely. We sent serum and CSF samples to a reference laboratory for testing for anti-NMDA receptor antibodies and other autoantibodies.

On the sixth hospital day, a repeat lumbar puncture was performed; the CSF white-cell count was 43 per cubic millimeter (91% lymphocytes). A CSF PCR assay for herpes simplex virus was again negative, ruling out the possibility of an initial false negative test. A 5-day course of intravenous methylprednisolone was initiated empirically.

CLINICAL DIAGNOSIS

Anti-N-methyl-D-aspartate (NMDA) receptor encephalitis.

DR. MARK P. GORMAN'S DIAGNOSIS

Anti-N-methyl-D-aspartate (NMDA) receptor encephalitis.

DIAGNOSTIC TESTING AND DISCUSSION OF MANAGEMENT

Dr. Gombolay: On the eighth hospital day, results of the assays performed at the reference laboratory returned positive for the detection of anti-NMDA receptor antibodies in serum and CSF specimens. These findings confirmed the diagnosis of anti-NMDA receptor encephalitis.

Anti-NMDA receptor antibodies were first identified in 2007 in patients who presented with new-onset psychosis, seizures, and autonomic dysfunction and had a response to immunotherapy.⁷ Among patients younger than 18 years of age, the most common manifestations of anti-NMDA receptor encephalitis include behavioral changes and seizures. Among children younger than 12 years of age, movement disorders are common. All these findings were seen in this patient. Among adults with anti-NMDA receptor encephalitis, the most prevalent findings are behavioral changes, seizures, cognitive dysfunction, and memory problems; movement disorders are seen less frequently in adults than in children.⁶

Anti-NMDA receptor encephalitis can be associated with tumors,⁶ but tumor-associated disease is uncommon in young children.⁸ Moreover, 94% of patients with tumor-associated anti-NMDA receptor encephalitis are female, and no cases of tumor-associated disease have been reported in boys.⁶ In this patient, imaging studies that were

performed to evaluate for the presence of a tumor — including ultrasonography of the thyroid and scrotum and MRI of the chest, abdomen, and pelvis — were all negative.

First-line treatment for anti-NMDA receptor encephalitis is intravenous glucocorticoids, intravenous immune globulin (IVIG), or plasma exchange. If a tumor is identified, surgical resection is also considered. In this patient, once the laboratory diagnosis had been confirmed, a 5-day course of IVIG was begun.

Dr. Pierce: Dr. Thibert, would you tell us what happened next?

Dr. Ronald L. Thibert: After the seizure occurred on the fifth hospital day, prompting transfer of the patient to the pediatric ICU, levetiracetam was administered and repeat MRI of the head was performed.

Dr. William A. Mehan, Jr.: Diffusion-weighted images and apparent-diffusion-coefficient maps showed symmetric restricted diffusion involving the cortex and subcortical white matter of the posterior cerebral hemispheres, and FLAIR images showed hyperintensity (Fig. 1A, 1B, and 1C). The imaging-based differential diagnosis included excitotoxic injury and encephalitis.

Dr. Thibert: Opisthotonic posturing and stereotyped movements of the mouth and arms continued, but these events were not epileptic. EEG continued to show slowing of the background with some asymmetry, but there was no clear epileptiform activity. The patient was treated with methylprednisolone and then IVIG; there was minimal clinical improvement. On the 12th hospital day, on completion of the 5-day course of IVIG, repeat MRI of the head was performed.

Dr. Mehan: The images showed new hyperintense signal and symmetric restricted diffusion involving the bilateral deep gray nuclei, with additional patchy areas of hyperintense signal in the subcortical white matter of the cerebral hemispheres (Fig. 1D, 1E, and 1F). These findings are consistent with the diagnosis of anti-NMDA receptor encephalitis.

Dr. Thibert: On the 13th hospital day, the patient had two more witnessed seizures. The dose of levetiracetam was increased, and a decision was made to begin weekly treatment with rituximab, given the severity of the patient's symptoms and the minimal response to first-line therapies. A second 5-day course of IVIG was also initiated.

On the 16th hospital day, episodes of staring

and eye fluttering occurred. Long-term EEG monitoring was initiated, and it revealed status epilepticus. A continuous infusion of intravenous midazolam was begun, and the dose of levetiracetam was again increased. The status epilepticus resolved, and the patient began to have electroclinical seizures that arose from the right hemisphere and then quickly generalized. Clobazam and valproic acid were added to the antiepileptic treatment regimen, and weekly doses of rituximab were continued.

On the 22nd hospital day, status epilepticus recurred; fosphenytoin therapy and a continuous infusion of pentobarbital were begun. The status epilepticus waxed and waned during the next 4 days. On the 27th hospital day, a ketogenic diet was started, and the next day, a continuous infusion of ketamine was begun. The fosphenytoin, clobazam, and valproic acid were stopped. By the 29th hospital day, the findings on EEG had improved markedly, with only occasional epileptiform activity.

Over the next several days, the dose of pentobarbital was gradually tapered, and the EEG findings worsened. By the 33rd hospital day, seizures originating in the right central region with generalization had recurred. Pentobarbital therapy was restarted, and the dose of midazolam was increased. The seizures resolved, and the dose of midazolam was gradually tapered. On the 40th hospital day, EEG showed runs of high-voltage sharp activity that appeared to be on the ictal-interictal spectrum. The pattern of seizure activity throughout the hospital course suggested that clinical worsening occurred just before each weekly rituximab treatment; therefore, a 7-day course of intravenous methylprednisolone was administered, followed by a prolonged tapering course of glucocorticoids. The ketogenic diet was stopped, both because its efficacy was uncertain and because the efficacy would decrease owing to hyperglycemia caused by the glucocorticoids. Ultimately, the doses of pentobarbital, ketamine, and midazolam were gradually reduced, without recurrence of seizures.

In addition to treatment-refractory seizures, the patient's clinical course was complicated by autonomic symptoms, diabetes insipidus, the syndrome of inappropriate antidiuretic hormone secretion, hypertriglyceridemia, and transient hypothyroidism. As part of the supportive care provided during the hospitalization, gastrostomy and tra-

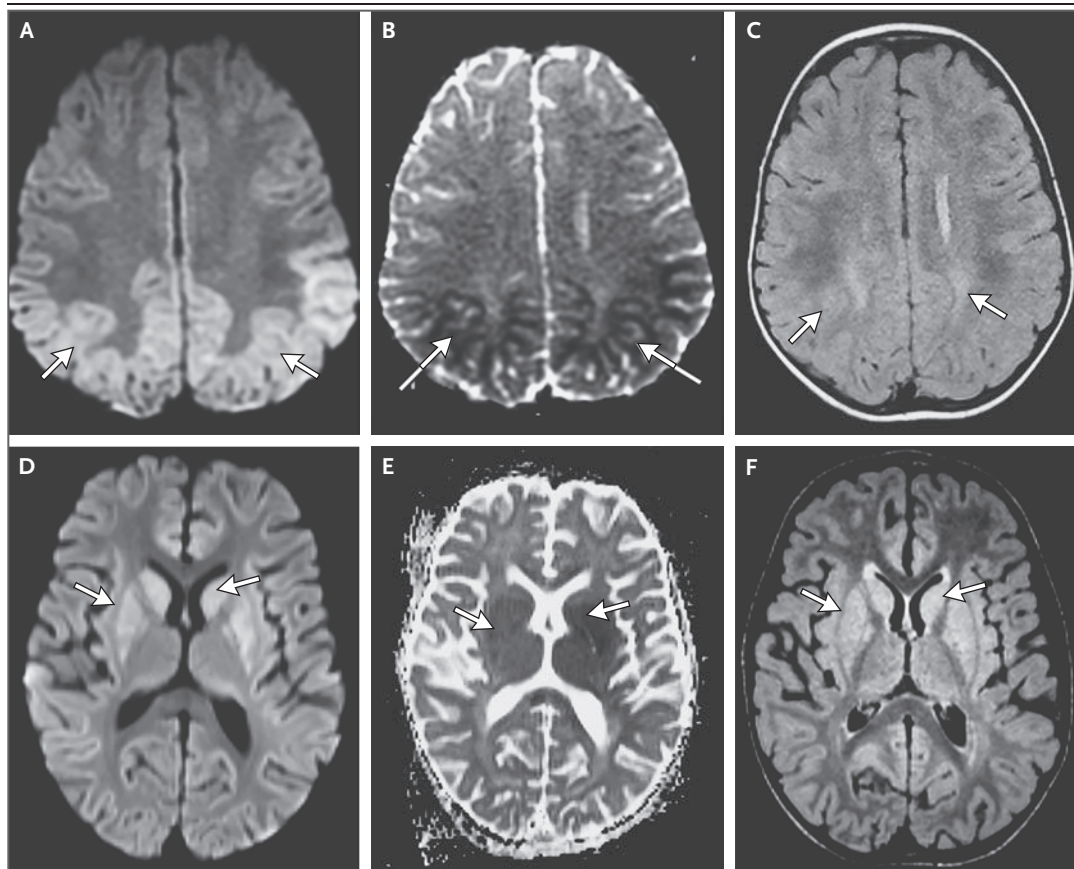


Figure 1. MRI of the Head.

MRI of the head was performed on the fifth hospital day of the second admission. An axial diffusion-weighted image (Panel A) and an axial apparent-diffusion-coefficient (ADC) map (Panel B) show symmetric restricted diffusion (arrows). A fluid-attenuated inversion recovery (FLAIR) image (Panel C) shows hyperintensity involving the cortex and subcortical white matter of the posterior cerebral hemispheres (arrows). Repeat MRI of the head was performed on the 12th hospital day of the second admission. An axial diffusion-weighted image (Panel D) and an axial ADC map (Panel E) show new areas of symmetric restricted diffusion (arrows). A FLAIR image (Panel F) shows hyperintensity involving the basal ganglia (arrows) and cerebellar hemispheres (not shown).

cheostomy tubes were placed. The patient was discharged to an inpatient rehabilitation facility after 3 months. He spent an additional 2 months at the rehabilitation facility. The gastrostomy and tracheostomy tubes were removed before he was discharged home.

On follow-up in the pediatric neurology clinic approximately 6 months after the first presentation, the patient's movement disorder had resolved. His gross motor skills were close to their baseline (pre-illness) level, and his fine motor skills were approaching their baseline level. He had some difficulties with sleep and hyperactivity and his speech was further delayed, but he was making progress in those areas.

Dr. Pierce: The results of MRI of the head performed on this patient's first presentation to the hospital had been normal. Dr. Mehan, are normal results on MRI common among patients with anti-NMDA receptor encephalitis?

Dr. Mehan: Results on MRI of the head are reportedly normal in half of patients with anti-NMDA receptor encephalitis. In the other half, T₂-weighted FLAIR images may reveal signal hyperintensity involving the hippocampi, cerebral or cerebellar cortex, basal ganglia, brain stem, and spinal cord, findings that were seen later in this patient's course.⁹ Contrast enhancement and restricted diffusion in the involved areas are less commonly encountered.¹⁰ Brain

atrophy may also be seen and is often reversible.¹¹

FINAL DIAGNOSIS

Anti-N-methyl-D-aspartate (NMDA) receptor encephalitis.

This case was presented at Pediatric Grand Rounds.

Dr. Mehan reports receiving fees for expert testimony from CRICO; and Dr. Thibert, receiving consulting fees from Ovid Therapeutics and Roche. No other potential conflict of interest relevant to this article was reported.

Disclosure forms provided by the authors are available with the full text of this article at NEJM.org.

We thank Dr. Carlos Torres for assistance with organization of the conference.

REFERENCES

1. Scheffer IE, Berkovic S, Capovilla G, et al. ILAE classification of the epilepsies: position paper of the ILAE Commission for Classification and Terminology. *Epilepsia* 2017;58:512-21.
2. Glaser CA, Honarmand S, Anderson LJ, et al. Beyond viruses: clinical profiles and etiologies associated with encephalitis. *Clin Infect Dis* 2006;43:1565-77.
3. Gable MS, Gavali S, Radner A, et al. Anti-NMDA receptor encephalitis: report of ten cases and comparison with viral encephalitis. *Eur J Clin Microbiol Infect Dis* 2009;28:1421-9.
4. Gable MS, Sheriff H, Dalmau J, Tilley DH, Glaser CA. The frequency of autoimmune N-methyl-D-aspartate receptor encephalitis surpasses that of individual viral etiologies in young individuals enrolled in the California Encephalitis Project. *Clin Infect Dis* 2012;54:899-904.
5. Graus F, Titulaer MJ, Balu R, et al. A clinical approach to diagnosis of autoimmune encephalitis. *Lancet Neurol* 2016;15:391-404.
6. Titulaer MJ, McCracken L, Gabilondo I, et al. Treatment and prognostic factors for long-term outcome in patients with anti-NMDA receptor encephalitis: an observational cohort study. *Lancet Neurol* 2013;12:157-65.
7. Dalmau J, Tüzün E, Wu HY, et al. Paraneoplastic anti-N-methyl-D-aspartate receptor encephalitis associated with ovarian teratoma. *Ann Neurol* 2007;61:25-36.
8. Remy KE, Custer JW, Cappell J, et al. Pediatric anti-N-methyl-d-aspartate receptor encephalitis: a review with pooled analysis and critical care emphasis. *Front Pediatr* 2017;5:250.
9. Dalmau J, Lancaster E, Martinez-Hernandez E, Rosenfeld MR, Balice-Gordon R. Clinical experience and laboratory investigations in patients with anti-NMDAR encephalitis. *Lancet Neurol* 2011;10:63-74.
10. Azizyan A, Albrektson JR, Maya MM, Pressman BD, Moser F. Anti-NMDA encephalitis: an uncommon, autoimmune mediated form of encephalitis. *J Radiol Case Rep* 2014;8:1-6.
11. Iizuka T, Yoshii S, Kan S, et al. Reversible brain atrophy in anti-NMDA receptor encephalitis: a long-term observational study. *J Neurol* 2010;257:1686-91.

Copyright © 2018 Massachusetts Medical Society.